

# Glaucoma

## TODAY

January/February 2012

# Reconsidering Transscleral Cyclophotocoagulation

A viable option for many types of glaucoma.

- ▶ Safety Profile of TSCPC
- ▶ Benefits of Noninvasive Glaucoma Surgery
- ▶ Benefits of the G-Probe in Practice
- ▶ The Future of TSCPC
- ▶ Case Study

# Reconsidering Transscleral Cyclophotocoagulation

INTRODUCTION BY DOUGLAS E. GAASTERLAND, MD

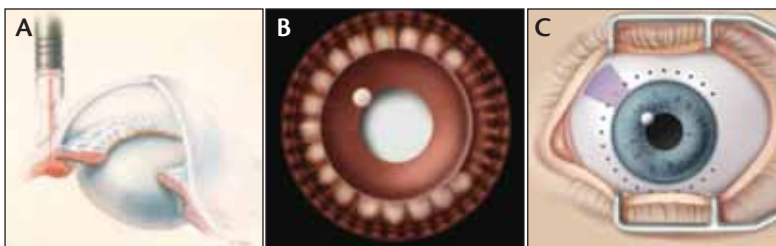
The objective of glaucoma management is to inhibit disease progression by providing a clinically significant, sustained drop in IOP in a way that preserves the patient's quality of life and has a favorable risk profile. These goals put pressure on ophthalmologists to find safe and effective surgical strategies that preclude the need to take patients to the OR.

Transscleral cyclophotocoagulation (TSCPC) devices were originally cleared for the treatment of patients with refractory glaucoma. These individuals often have medical conditions that increase the systemic risks of an invasive glaucoma operation.

Weekers and associates introduced the use of light—in the form of xenon arc optical energy—as the cyclodestructive element in a transscleral application in the 1960s.<sup>1</sup> When Nd:YAG and semiconductor diode laser systems became available in the mid-1980s, TSCPC finally became a viable option.

Aqueous humor is formed by a combination of ultrafiltration through fenestrated ciliary process capillaries and secretion by the pigmented and nonpigmented epithelium of the inner surface of the ciliary processes. TSCPC reduces aqueous humor production by coagulating proteins inside and next to pigmented cells. The procedure closes nearby capillaries and ablates the ciliary epithelium without destroying the ciliary body itself. This slows aqueous humor production. Other than its effects on the ciliary body, TSCPC does not alter the anatomy of the eye or the conjunctiva, which makes the procedure repeatable and titratable. The only eligibility requirement for treatment is that the eye has some degree of functioning aqueous outflow. TSCPC then reduces aqueous inflow to match outflow, thereby reducing IOP.

The procedure is usually performed with contact fiber optic delivery of either infrared (1,064 nm) Nd:YAG or near-infrared (about 810 nm) diode laser light energy. Additional



**Figure.** TSCPC. G-Probe's placement and alignment at limbus (A). Posterior view of G-Probe treatment. Note pale burns of several ciliary processes with each application (B). The width of the probe (purple shadow) helps determine the next placement (red dot) of the G-Probe at evenly spaced treatment sites (dark dots), typically 19 to 21 sites (C).

wavelengths have been studied, but the 810-nm diode light has become the leading modality. The energy is delivered via a handpiece with a 600- $\mu$ m-diameter quartz glass fiber that is called a *G-Probe* (Iridex Corporation). The fiber has a protruding, polished, hemispheric tip, and the probe has a conforming scleral footplate for better orientation on the eye. By indenting the conjunctiva and centering the fiber optic tip 1.2 mm from the corneoscleral limbus oriented parallel to the visual axis, the G-Probe places the laser energy where it needs to be (Figure). Peribulbar or retrobulbar anesthesia is required, because the laser applications would otherwise be too uncomfortable for the patient. Laser delivery does not require an incision, so patients can receive treatment in the office rather than in the OR. This provides the possibility of immediate treatment when the situation is urgent.

Although surgeons have implemented TSCPC for challenging cases of recalcitrant glaucoma in recent years, the procedure may have wider applications. Specifically, TSCPC as an outpatient procedure is an attractive alternative to invasive glaucoma surgery. In the following pages, leading glaucoma experts discuss the applications of TSCPC and share their personal experiences and opinions. ■

1. Weekers R, Laverne G, Watillon M, Gilson M, Legros AM. Effects of photocoagulation of ciliary body upon ocular tension. *Am J Ophthalmol.* 1961;52:156-163.

## Faculty

---



### **Douglas E. Gaasterland, MD**

Douglas E. Gaasterland, MD, is in private practice with Eye Doctors of Washington DC in Chevy Chase, Maryland. He has served as a medical advisor to, has received research support from, and holds stock in Iridex Corporation. Dr. Gaasterland, with an Iridex employee, developed the G-Probe for the diode laser treatment of glaucoma, and Georgetown University receives royalty payments in the author's name for G-Probe sales. Dr. Gaasterland may be reached at (301) 215 7100; degaasterland@edow.com.



### **Nathan M. Radcliffe, MD**

Nathan M. Radcliffe, MD, is an assistant professor of ophthalmology and director of the glaucoma service at Weill Cornell Medical College, New York-Presbyterian Hospital, New York. He has received honoraria or speaker's fees from Iridex Corporation. Dr. Radcliffe may be reached at (646) 962-2020; drradcliffe@gmail.com.



### **Steven D. Vold, MD**

Steven D. Vold, MD, is chief executive officer of and a glaucoma and cataract surgery consultant at Vold Vision, PLLC, Bentonville, Arkansas. He has received lecture honoraria from Iridex Corporation as well as the recent licensure of his intellectual property as part of Ocunetics, Inc., to Iridex. Dr. Vold may be reached at (479) 756-8653; svold@cox.net.



### **Jeffrey A. Kammer, MD**

Jeffrey A. Kammer, MD, is an assistant professor of ophthalmology & visual sciences, and he is the chief of the Glaucoma Service at Vanderbilt Eye Institute in Nashville, Tennessee. He has received honoraria or speaker's fees from Iridex Corporation. Dr. Kammer may be reached at (615) 936-7190; jeff.kammer@vanderbilt.edu.

## Contents

---

Safety Profile of TSCPC .....	4
Benefits of Noninvasive Glaucoma Surgery .....	6
Benefits of the G-Probe in Practice .....	7
The Future of TSCPC .....	9
Case Study .....	10

# Safety Profile of TSCPC

## BACKGROUND OF CYCLODESTRUCTIVE PROCEDURES

Cyclodestruction has long been viewed as a therapeutic approach largely reserved for the management of refractory glaucomas. Cyclodestruction, originally performed using diathermy, and later cryotherapy, was reserved for the worst cases of uveitic or neovascular glaucoma (NVG). These techniques were associated with serious complications, such as substantial posttreatment visual loss, sympathetic ophthalmia, and phthisis. With recent advances in laser technology and application techniques, the therapeutic role of cyclophotocoagulation is being expanded, and previous glaucoma treatment paradigms are being challenged.

In one study, investigators reviewed 68 eyes of 64 patients treated with cyclocryotherapy and found a mean decrease in IOP of between 8 and 24 mm Hg.<sup>1</sup> This reduction was accompanied by visual loss in 30% of patients, and almost 12% of total patients experienced phthisis. Dr. Kammer elucidates, “When you really read the article, you’ll see that a vast majority of the patients had NVG, and the second-largest group was patients with aphakic glaucoma, both very difficult-to-treat glaucoma cases. Moreover, of the 12% who developed phthisis, 75% of them had NVG. So, certainly you’re looking at the most difficult patients to treat. Historically, these are the patients who physicians recommend undergo cyclodestructive procedures.”

## ASSESSING THE RISKS

Transscleral cyclophotocoagulation (TSCPC) has largely replaced cyclocryotherapy. Dr. Kammer points out that, in a study directly comparing the two approaches,<sup>2</sup> “both methods yield excellent IOP decreases of over 60%. However, the side effect profile was much improved in the diode TSCPC group. Most notably, the incidence of profound visual loss was 6% for TSCPC compared to 16% for cyclocryotherapy; the incidence of phthisis was 3% for TSCPC compared to 5% for cyclocryotherapy. Again, it’s important to note that the vast majority of these patients had NVG.”

A technical assessment completed by the American Academy of Ophthalmology (AAO) declared that “cyclophotocoagulation is indicated for patients with refractory glaucomas who have failed trabeculectomy or tube shunt procedures, patients with minimal useful vision and elevated intraocular pressure, patients who have no visual potential and need pain relief, and patients with complicated glaucoma and conjunctival scarring from previous surgery.”<sup>3</sup> According to Dr. Vold, “These high-risk patients would likely have poor results with any surgical procedure.” He shares some of the reasons for post-TSCPC vision loss within this group:

---

“High-risk patients would likely have poor results with any surgical procedure.”

— Dr. Vold

---

- **Cataract.** Postoperative inflammation and topical steroid use may predispose eyes to cataract development.
- **Chronic inflammation.** If a patient has long-standing inflammation, which is common in sick eyes, he or she likely will not do very well after any surgical intervention. Choroidal effusions or retinal detachments can also occur in these cases.
- **Cystoid macular edema.** Surgically induced cystoid macular edema is one of the more common reasons for vision loss.
- **Neurotrophic cornea.** TSCPC can damage corneal nerves that will reduce corneal sensation and make the patient more prone to infections of the cornea and neurotrophic ulcers.
- **Sympathetic ophthalmia.** Several publications have reported an inflammatory response in one eye subsequent to TSCPC treatment in the fellow eye.<sup>4,5</sup>

Dr. Radcliffe agrees with Dr. Vold’s assessment. “Reviewing the literature on TSCPC, it is a procedure that has been used on a lot of sick eyes,” he states. “You end up inheriting whatever those sick eyes brought to the table as part of your side effect profile. In a prospective, randomized study of one eye of each of 92 patients with primary open-angle glaucoma that underwent TSCPC, the drop in IOP was 20% or more in 47% of patients, with a final IOP of 22 mm Hg or lower in 48% of patients.<sup>6</sup> In addition, 13 months postsurgery, visual acuity decreased in 23% of eyes treated with TSCPC as well as in 23% of fellow eyes treated only with medication. This demonstrates the point that, while there was some loss of visual acuity post-TSCPC, vision loss was probably more related to the type of eye rather than to any specific treatment effect.”

## TSCPC COMPARED TO THE GOLD STANDARD

The risk of complications with TSCPC is similar to that for tube shunt surgery and trabeculectomy, the gold standards in glaucoma treatment. In the 3-year follow-up for the Tube Versus Trabeculectomy (TVT) Study, 212 eyes were randomized to either the 350-mm<sup>2</sup> Baerveldt glaucoma implant (Abbott Medical Optics Inc.) or a trabeculectomy with mitomycin C.<sup>7</sup> Three years after surgery, the average decrease in IOP for both groups was 48%, and surgical com-

plications related to reoperation or a visual acuity loss of greater than 2 Snellen lines occurred in 22% of the tube group and 27% of the trabeculectomy group.

Dr. Radcliffe notes the similarity of these results to those of a study of 74 eyes that underwent TSCPC and were followed for 12 months.<sup>8</sup> This group had a mean IOP reduction of 43%. Mean visual acuity was preserved in the subgroups with good vision, whereas 13% of patients lost vision due to a progressive cataract or glaucoma. “It’s important always to look at these studies and see why someone lost vision,” he remarks. “In this study, there were no cases of hypotony or phthisis. Suprachoroidal hemorrhage is really the dreaded complication of incisional glaucoma surgery, and it’s just not something that you see after TSCPC, because hypotony—and particularly the sudden hypotony that can lead to a hemorrhage—is avoided.”

Dr. Kammer likewise cites the favorable results of a comparative study by Yildirim and colleagues.<sup>9</sup> “In this study, 66 patients were randomized to receive diode TSCPC or the Ahmed Glaucoma Valve (New World Medical, Inc.,” he says. “In the diode laser group, there was a 57% reduction in IOP, whereas the Ahmed group had a 47% decrease in IOP, both excellent. Interestingly, both groups had an incidence of decreased vision of about 25%. Remember, these are predominately NVG patients who are very difficult to treat. They’re going to lose vision from macular edema, from ischemia, and from just recurrent hemorrhage. There was actually no phthisis in the TSCPC group and a low 6% incidence in the Ahmed group. This shows us that the concern over loss of visual acuity is merely referencing old literature.” This study also concludes that TSCPC is less time consuming and an easier method for lowering IOP in patients with NVG.

Dr. Kammer expands on the data from the TVT Study with research on eyes with good vision. “The Rotchford data on TSCPC show 18% of patients (n = 49) with 20/60 or better vision experienced visual loss,”<sup>10</sup> he says. “The Advanced Glaucoma Intervention Study (AGIS) showed that 40% of patients with medically uncontrolled glaucoma treated with either trabeculectomy or argon laser trabeculectomy had a 3- or more line reduction in visual acuity at the 5-year follow-up.<sup>11</sup> In both cases, TSCPC compares very favorably.”

As Dr. Radcliffe points out, tube shunts fail: “Nouri-Mahdavi and Caprioli reviewed 156 consecutive cases of implantation of an Ahmed valve and found that 56% of cases passed through a hypertensive phase.<sup>12</sup> Of those patients that suffered a hypertensive phase, only 28% achieved resolution. This is primary failure of a tube that was put in a perfect position and had no complications. Once that happens, your options are pretty limited. You can put in a second tube, do a tube revision, or look for another option.”

Data from a study of 22 eyes show that, when a second tube is placed in eyes where the first tube failed, 45% of these eyes developed corneal edema, and a quarter of them required a corneal transplant.<sup>13</sup> The numbers are no better for a revised tube. A study comparing tube revisions (n = 12) to placing a second tube (n = 21) showed that 43% of the revisions and 62% of the second tubes achieved a drop in IOP of greater than 25%. Corneal edema, however, occurred in 42% and 43% of the cases, respectively.<sup>14</sup>

In contrast, in a study of TSCPC after a failed tube shunt, 71% of 21 eyes achieved success; of these eyes, 33% required additional TSCPC sessions.<sup>15</sup>

“To me, there’s a difference between going back to the OR and incising the eye again and just performing more laser treatment in a nonincisional fashion,” Dr. Radcliffe comments. “So, a retreatment rate of 33%, I think, is acceptable. A small percentage of patients lost light perception in that series, but we know that these are sick eyes.”

## CONCLUSION

Dr. Radcliffe summarizes the situation as follows: “We see there is a pretty good response rate to TSCPC across all different types of glaucoma, even in traumatic eyes or when compared to gold-standard treatments like trabeculectomy. In addition, the only firm contraindication is a patient with total occlusion of outflow. Together, these factors create great potential in this treatment.” ■

1. Benson MT, Nelson ME. Cyclocryotherapy: a review of cases over a 10-year period. *Br J Ophthalmol.* 1990;74(2):103-105.
2. Goldenberg-Cohen N, Bahar I, Ostashinski M, et al. Cyclocryotherapy versus transscleral diode laser cyclophotocoagulation for uncontrolled intraocular pressure. *Ophthalmic Surg Lasers Imaging.* 2005;36(4):272-279.
3. Pastor SA, Singh K, Lee DA, et al. Cyclophotocoagulation: a report by the American Academy of Ophthalmology. 1. Prepared by the Ophthalmic Technology Assessment Committee Glaucoma Panel and approved by the American Academy of Ophthalmology’s board of trustees August 1, 2001. *Ophthalmology* 2001;108(11):2130-2138.
4. Kumar N, Chang A, Beaumont P. Sympathetic ophthalmia following ciliary body laser cyclophotocoagulation for rubeotic glaucoma. *Clin Experiment Ophthalmol.* 2004;32(2):196-198.
5. Roberts MA, Rajkumar V, Morgan G, Laws D. Sympathetic ophthalmia secondary to cyclodiode laser in a 10-year-old boy. *J AAPOS.* 2009;13(3):299-300.
6. Egbert PR, Fiadoyor S, Budenz DL, et al. Diode laser transscleral cyclophotocoagulation as a primary surgical treatment for primary open-angle glaucoma. *Arch Ophthalmol.* 2001;119:345-350.
7. Gedde SJ, Schiffman JC, Feuer WJ, et al. Three-year follow-up of the tube versus trabeculectomy study. *Am J Ophthalmol.* 2009;148(5):670-684.
8. Ansari E, Gandhewar J. Long-term efficacy and visual acuity following transscleral diode laser photocoagulation in cases of refractory and non-refractory glaucoma. *Eye (Lond).* 2007;21(7):936-940.
9. Yildirim N, Yalvac IS, Sahin A, et al. A comparative study between diode laser cyclophotocoagulation and the Ahmed Glaucoma Valve implant in neovascular glaucoma: A long-term follow-up. *J Glaucoma.* 2009;18(3):192-196.
10. Rotchford AP, Jayasawal R, Madhusudhan S, et al. Transscleral diode laser cycloablation in patients with good vision. *Br J Ophthalmol.* 2010;94(9):1180-1183.
11. The Advanced Glaucoma Intervention Study (AGIS): 4. Comparison of treatment outcomes within race. Seven-year results. *Ophthalmology.* 1998;105(7):1146-1164.
12. Nouri-Mahdavi K, Caprioli J. Evaluation of the hypertensive phase after insertion of the Ahmed Glaucoma Valve. *Am J Ophthalmol.* 2003;136(6):1001-1008.
13. Burgoyne JK, WuDunn D, Lakhani V, Cantor LB. Outcomes of sequential tube shunts in complicated glaucoma. *Ophthalmology.* 2000;107(2):309-314.
14. Shah AA, WuDunn D, Cantor LB. Shunt revision versus additional tube shunt implantation after failed tube shunt surgery in refractory glaucoma. *Am J Ophthalmol.* 2000;129(4):455-60.
15. Semchishyn TM, Tsai JC, Joos KM. Supplemental transscleral diode laser cyclophotocoagulation after aqueous shunt placement in refractory glaucoma. *Ophthalmology.* 2002;109(6):1078-1084.

## Benefits of Noninvasive Glaucoma Surgery

In all of medicine, there has been a movement during recent years toward less invasive procedures that have shorter healing times, fewer complications, and lower costs and that improve patients' overall quality of life. Ophthalmologists have looked for alternative procedures that are equally effective but can be conducted on an outpatient basis.

Topical medications are the most widely used first line of treatment for glaucoma, despite dismal compliance rates, because clinicians want to keep patients out of the OR. Although transscleral cyclophotocoagulation (TSCPC) has been used for a number of years, it has often been overlooked as a flexible outpatient procedure, primarily due to its association with late-stage glaucoma such as neovascular glaucoma. It is time to rethink TSCPC's place in the treatment paradigm.

As Dr. Kammer notes, "The main advantages of transscleral cyclodestructive procedures, compared with filtration and drainage devices, are that they can be performed on an outpatient basis in a minor procedure room using a nonsterile technique. Technically, TSCPC is very easy to learn and easy to perform." He adds, "There is a quick recovery, with patients typically back to normal within a

week, and most importantly, there is no risk of infection, as is inherent with incisional surgery."

Dr. Vold agrees. "Office-based glaucoma surgery, such as TSCPC, can really save patients and the health care system a significant amount of money in facility fees while providing patients with excellent medical care," he says. "Another benefit is that the recovery is much more rapid and the postoperative care much less involved than with someone who has had an incisional glaucoma case in a surgical center."

TSCPC also offers the benefit of flexibility. "TSCPC can be used for a wide range of glaucomas," Dr. Vold explains. "It can be used for open-angle glaucoma as well as angle-closure glaucomas. Really, almost all types of glaucoma can potentially be treated with TSCPC."

TSCPC can be performed urgently, because patients need not stop anticoagulants beforehand. The procedure's effects can be seen immediately. Moreover, TSCPC can be performed after any other surgery and does not limit future surgical options. In addition, TSCPC can be repeated as necessary, which allows surgeons to titrate the treatment to the needs of a specific patient.

### TECHNICAL DESCRIPTION OF THE G-PROBE

The G-Probe is a noninvasive fiber optic laser handpiece that allows the selective ablation of the ciliary processes (Figure). The G stands for Dr. Gaasterland, one of the inventors, and for glaucoma. The laser energy is transmitted by a quartz fiber with a 600- $\mu$ m diameter and a special hemispheric tip. The probe has curves on the footplate that correspond to the limbal and scleral curvatures for a better localization and orientation with the eye. The G-Probe centers the fiber optic tip 1.2 mm from the corneoscleral limbus and encourages orientation of the fiber optic parallel to the visual axis to efficiently deliver laser energy where it needs to be. In addition, the tip extends 0.7 mm from the base of the footplate, thereby pressing down on the conjunctival sclera to enhance transmission, again improving efficiency.

In addition to using the diode laser system for TSCPC, Dr. Vold has used it for other applications, including suture lysis, pupilloplasty, sphincterotomies, and even cyclodialysis clefts. "Laser energy directed toward the bed of the cyclodialysis cleft will cause inflammation and potentially will lead to closure of the cleft," says Dr. Vold. "Even bleb leaks have been treated with lasers in the past."



Figure. The G-Probe.

Although predominantly associated with glaucoma procedures, the laser system is actually multifunctional, according to Dr. Kammer. "Not only can it be used for glaucoma procedures, but it also is widely used for retinal procedures," he notes. "That is often overlooked yet so very important, particularly in this age of decreased reimbursement."

---

“TSCPC is a surgery that can be done before or after any other surgery. It is very versatile from that standpoint.”

— Dr. Radcliffe

---

Dr. Radcliffe says, “I actually challenge you to think about this for a minute. Name one surgery that really can be performed after any other and that really doesn’t limit your next surgery. Canaloplasty (iScience Interventional) can’t be performed after Trabectome (NeoMedix Corporation) or an iStent (Glaukos Corporation; not available in the United States), and a tube shunt is more difficult to place after a trabeculectomy. You run out of space and have scarring. So, TSCPC is a surgery that can be done before or after any other surgery. It is very versatile from that standpoint.”

Dr. Vold cites a study of 21 eyes with 20/80 or better visual acuity as evidence that TSCPC should not be reserved for end-stage cases.<sup>1</sup> “Interestingly, [the investigators] found that 17 of 21 patients maintained their vision within 1 line of their baseline visual acuity during the mean follow-up period of 40.7 months (range, 13-88 months),” he says. “The conclusion here is that TSCPC should not necessarily be limited to eyes with just poor visual potential. This was very enlightening to me, because I had been taught to fear TSCPC.”

TSCPC offers several other benefits as well. “One of the big things that we have going for us with TSCPC is you don’t have to worry about endophthalmitis, as this is a noninvasive surgery,” remarks Dr. Vold. Eliminating the possibility of infection is a significant

benefit for many patients, especially those in poor health and less than ideal candidates for incisional glaucoma surgery.

According to Dr. Radcliffe, TSCPC has the right mix of effectiveness, risk, and expense, and it is also easy to perform. “Surgeries that have a big learning curve are uncomfortable for many surgeons, because we don’t want to put our patients through that,” he says. “Ethically, this is often something that we discuss. How do I get to the point where I can do the new surgery and deliver the type of outcomes that I want for my patients? [TSCPC] really doesn’t have much of a learning curve in terms of technique.”

Although silicone oil is a useful therapy in a variety of complex vitreoretinal cases, it has been known to increase IOP.<sup>2</sup> Dr. Radcliffe shares, “When you try to put a tube in an eye with silicone oil, it gets clogged, and other incisional surgeries also get very complicated. Glaucoma can, however, be treated very easily with TSCPC in these eyes.”

Another advantage of TSCPC, Dr. Vold says, is that “it’s successful in reducing IOP in 70% to 75% of patients. The laser is compact and extremely low maintenance, and it provides a relatively low incidence of complications such as phthisis and postoperative pain.”

All of these advantages make TSCPC worthy of consideration, argues Dr. Kammer. “Diode cyclophotocoagulation is actually a viable option for many different types of glaucoma, and it should not just be considered in those patients who are worst-case scenarios,” he says. ■

1. Wilensky JT, Kammer J. Long-term visual outcome of transscleral laser cyclotherapy in eyes with ambulatory vision. *Ophthalmology*. 2004;111(7):1389-1392.

2. Henderer JD, Budenz DL, Flynn HW Jr, et al. Elevated intraocular pressure and hypotony following silicone oil retinal tamponade for complex retinal detachment: incidence and risk factors. *Arch Ophthalmol*. 1999;117(2):189-195.

---

## Benefits of the G-Probe in Practice

---

Transscleral cyclophotocoagulation (TSCPC) is recognized as an excellent therapeutic approach to complex refractory glaucomas. According to Dr. Kammer, however, the procedure has many more applications. “You can really consider TSCPC in almost all glaucoma situations, even malignant glaucoma,” he says. “It is not just relegated to end-stage treatment anymore.”

Research shows that TSCPC should not be reserved for patients with poor vision. Dr. Kammer coauthored a retrospective study of 21 eyes with a Snellen visual acuity of greater than 20/80 before laser therapy.<sup>1</sup> He reports, “While

17 of the 21 individuals did need additional laser or surgical adjunctive treatment to reach the target IOP range, in 81% of patients, their vision remained within 1 line of the pretreatment vision.” Dr. Vold comments on Dr. Kammer’s research: “This was one of the first studies of TSCPC on eyes with good vision, and the results are really powerful. Clearly, the procedure should not be reserved solely for patients with poor vision.”

Dr. Kammer’s results are supported by a retrospective study by Rotchford and associates in which they evaluated 49 eyes with a pretreatment Snellen visual acuity that

was greater than or equal to 20/60.<sup>2</sup> The primary outcome variable in this study was a recorded visual loss of 2 or more Snellen lines of BCVA during an almost 8-year follow-up period, an outcome experienced by 31% of patients. Dr. Kammer analyzes the results: “On the positive side, over two-thirds of the patients retained vision greater than or equal to 20/60. There was a 2- or more line drop in a little less than a third of the patients, which could be a bit [of a concern]. If you look at the mean survival time of almost 8 years, however, you can see that a lot of these are just normal glaucoma progression.”

A prospective study by Egbert and associates in Ghana examined the effects of TSCPC as a primary surgical treatment in one eye of patients with primary open-angle glaucoma.<sup>3</sup> The other eye was treated medically with a standard protocol. Seventy percent (n = 49) of patients experienced no change in visual acuity, 6% gained visual acuity, and 23% showed a decrease in visual acuity. “When you look at the results more carefully, you can see that, with the 19 eyes with a pretreatment visual acuity of 20/60 or better, only one patient [’s disease] progressed,” says Dr. Kammer. “Most importantly, there was no significant difference in vision between eyes with [TSPCP] and the fellow medically treated eye. This suggests that some of the loss of visual acuity is normal glaucoma progression that you can see with or without treatment and not necessarily secondary to the diode laser treatment.”

Ansari and Gandhewar evaluated the long-term safety and efficacy of TSCPC with a particular emphasis on the posttreatment visual acuity in sighted eyes.<sup>4</sup> Their retrospective analysis included 74 treated eyes observed for a little over 1 year. A subset of 23 eyes with primary open-angle glaucoma and a mean pretreatment visual acuity of 20/60 underwent a single TSCPC treatment. Dr. Kammer comments, “The mean visual acuity did not

“You can really consider TSCPC in almost all glaucoma situations, even malignant glaucoma. It is not just relegated to end-stage treatment anymore.”

— Dr. Kammer

change at all in this subset, and you can see that there is no difference at all between the mean pretreatment visual acuity and the mean posttreatment visual acuity (Table). In some cases, visual acuity will actually improve after TSCPC, as was the case with 15%.” Visual acuity improved after treatment in two of 13 eyes (15.4%) in a study of TSCPC for medically uncontrolled chronic angle-closure glaucoma.<sup>5</sup> “With these data,” Dr. Kammer says, “we should feel comfortable using TSCPC on eyes with good vision.”

Dr. Kammer presents a case to illustrate TSCPC’s utility in cases of pigmentary glaucoma secondary to iris tumors. A 65-year-old white woman had a visual acuity of 20/100 OD second to amblyopia and 20/20 OS. She was diagnosed with an iris melanocytoma in her left eye. An excisional biopsy was recommended to verify the diagnosis, but the patient elected observation instead in an effort to preserve the sight in her “good” eye. Over time, her IOP began to rise. “When I first saw the patient, her pressure was up to 35 mm Hg, despite being on four medications,” says Dr. Kammer. “Hesitant to recommend filtering surgery, we opted for TSCPC. On the first day postoperation, her vision was 20/50, and her pressure was a bit high. By 3 weeks postoperatively, her vision was back to normal, 20/20, and she was on one medication twice a day. So, this is an excellent indication for using the diode laser.”

**TABLE. LOWERING THE IOP WITH A DIODE LASER**

Diagnostic Category	No. of Eyes (% total)	Mean Age of Patients (standard deviation)	Mean No. of Treatments	Mean IOP Before Laser Treatment, mm Hg	Mean IOP After Laser Treatment, mm Hg	Mean Change in IOP, %	Mean Preoperative Visual Acuity	Mean Postoperative Visual Acuity
All eyes	74 (100)	75.7 (8.7)	1.01	40.3	21.1	45.1		
Neovascular	37 (50)	75.1 (8.3)	1.02	48.2	25.3	47.0		
POAG	23 (31)	79.2 (10.8)	1.0	28.6	16.1	39.0	6/22	6/19
CACG	6 (8)	66.7 (7.1)	1.0	35.0	23.0	29.9	6/26	6/29

Data adapted from Ansari and Gandhewar.<sup>4</sup>

Abbreviations: POAG, primary open-angle glaucoma; CACG, chronic angle-closure glaucoma.



“We should feel comfortable using TSCPC on eyes with good vision.”

— Dr. Kammer

Dr. Vold argues that TSCPC is also a viable treatment option in glaucoma patients after corneal transplantation. “I really think these are excellent candidates,” he says. “Transillumination to accurately identify the location of the ciliary processes is critical in these patients due to the scarring around the limbus. While this may not be the first-line therapy, for uncontrolled glaucoma or patients that are noncompliant with their drops, this is a good option.”

In addition, Dr. Vold considers TSCPC to be a reasonable treatment option for phakic patients. “I have used this procedure many times in phakic patients with neovascular

glaucoma,” he comments. “TSCPC provides safe and highly effective treatment in this patient population. When utilizing a transillumination-guided surgical approach, I have never had anyone develop a white cataract with this treatment. With proper surgical technique, the risks commonly associated with TSCPC can be greatly reduced.”

Both Dr. Kammer and Dr. Vold note that patients can do very well with minimal side effects after TSCPC. ■

1. Wilensky J, Kammer J. Long term visual outcomes of transscleral laser cyclotherapy in eyes with ambulatory vision. *Ophthalmology*. 2004;111(7):1389-1392.
2. Rotchford AP, Jayasawal R, Madhusudhan S, et al. Transscleral diode laser cycloablation in patients with good vision. *Br J Ophthalmol*. 2010;94(9):1180-1183.
3. Egbert PR, Fiadoyor S, Budenz DL, et al. Diode laser transscleral cyclophotocoagulation as a primary surgical treatment for primary open-angle glaucoma. *Arch Ophthalmol*. 2001;119:345-350.
4. Ansari E, Gandhewar J. Long-term efficacy and visual acuity following transscleral diode laser photocoagulation in cases of refractory and non-refractory glaucoma. *Eye (Lond)*. 2007;21(7):936-940.
5. Lai JS, Tham CC, Chan JC, Lam DS. Diode laser transscleral cyclophotocoagulation as primary surgical treatment for medically uncontrolled chronic angle closure glaucoma: long-term clinical outcomes. *J Glaucoma*. 2005;14(2):114-119.

## The Future of TSCPC

Diode transscleral cyclophotocoagulation (TSCPC) has a relatively high efficacy rate<sup>1</sup> while avoiding many of the complications inherent in incisional glaucoma surgery.<sup>2</sup> As laser technology has evolved, so have physicians’ techniques.

### SLOW COAGULATION

Described by Dr. Gaasterland, this technique represents a reconsideration of the endpoint of TSCPC.<sup>3</sup> Originally, surgeons applied laser energy until they heard a little “pop” and then titrated treatment to that level. The audible pop occurs when the threshold from coagulation to tissue vaporization is exceeded. “The goal here is not to hear the

pop,” explains Dr. Radcliffe. “You don’t increase the energy if you aren’t hearing pops; you just treat. Advocates of this technique believe that, if you hear the pop, you’ve destroyed more tissue than you would like to.”

The slow-coagulation technique uses a lower level of power but for a longer duration than previous techniques (Table). Dr. Radcliffe comments, “Even less power is used if treating a brown iris, as the heavy brown pigmentation will absorb the laser light and also have more of a thermal response.”

“You are still delivering a significant amount of energy with each application to the ciliary body epithelium while reducing the postoperative inflammatory response some-

**TABLE. COMPARISON OF ORIGINAL APPROACH TO TSCPC WITH DR. GAASTERLAND’S SLOW-COAGULATION TECHNIQUE**

Technique	Iris Color	Power, mW	Duration, ms	Energy per Application, J
Original <sup>a,b</sup>	Dark	1,500	2,000	3
	Light	1,750	2,000	3.5
Slow coagulation <sup>c</sup>	Brown	1,250	4,000	5
	All others	1,500	3,500	5.25

<sup>a</sup>Titrate to occasional “pops.”

<sup>b</sup>Data adapted from Kosoko O, Gaasterland DE, Pollack IP, Enger CL. Long-term outcome of initial ciliary ablation with contact diode laser transscleral cyclophotocoagulation for severe glaucoma. *The Diode Laser Ciliary Ablation Study Group*. *Ophthalmology*. 1996;103(8):1294-1302.

<sup>c</sup>No-pop technique described by Gaasterland.<sup>3</sup>

times seen with higher-powered laser blasts,” reports Dr. Vold. “Dr. Gaasterland found that he could obtain results as good as if using a higher-powered laser for less time. A lot of surgeons have moved to this technique.”

### TRANSILLUMINATION

Identifying the location of the ciliary processes with a fiber optic light source is a useful technique in a variety of cases. “Transillumination is especially critical in postcorneal transplant and myopic patients, because the ciliary processes may appear to be in a more posterior location than expected,” Dr. Vold explains. “If you do the procedure blindly, you’re not going to have consistently good results in these cases. A pen light or even an indirect ophthalmoscope light held off to the side of the eye will help surgeons isolate the location of the ciliary processes. I personally use a transillumination-guided surgical approach in all TSCPC cases.”

### MICROPULSE

MicroPulse treatment is becoming popular in many areas of ophthalmic surgical practice as a way to reduce collateral tissue damage and associated side effects. MicroPulse technology chops a continuous-wave laser beam into a train of repeated short, microsecond, “on” pulses followed by longer-duration “off” intervals that allows for thermal relaxation of the tissue during the “off” portion to reduce thermal buildup.

Researchers used a specially modified G-Probe (not commercially available at this time) to perform MicroPulse TSCPC on 40 eyes of 38 consecutive patients with refractory glaucomas.<sup>4</sup> The mean baseline IOP was 39.3 mm Hg, and the patients were observed for 16.3 months. The MicroPulse treatment protocol consisted of 2,000 mW of 810-nm infrared diode laser radiation, delivered with a painting-type technique during 100 seconds. A train of micropulses was delivered with the laser on for 0.5 milliseconds and then off for 1.1 milliseconds for a period of 1.6 milliseconds (a duty cycle of 31.3%, 625 pps). Half of

---

“Transillumination is especially critical in postcorneal transplant and myopic patients, because the ciliary processes may appear to be in a more posterior location than expected.”

— Dr. Vold

---

those pulses were delivered in 50 seconds to the superior quadrant and the remaining half to the inferior quadrant. The 3- and 9-o’clock meridians were spared, along with any area of thinned sclera. “The concept here is that, by allowing the tissue to cool between pulses, the thermal spread is reduced,” Dr. Radcliffe explains. “The amount of tissue destruction, and perhaps pain, is going to be reduced as well, despite the delivery to each eye of 62.6 J.”

The mean IOP 12 months after surgery was 26.6 mm Hg, or a 33% drop in IOP. No patient had hypotony or lost BCVA, and 10% actually experienced an improvement in their visual acuity. The overall success rate, defined as an IOP of less than 21 mm Hg or a 30% reduction without medications, was 72.7% after a mean of 1.3 treatment sessions. Dr. Vold comments, “MicroPulse allows you to get a lot of treatment but with significantly less energy in the eye. It’s a kinder, gentler approach to TSCPC.” Dr. Kammer adds, “MicroPulse TSCPC is a very exciting innovation that’s coming up in the future, which allows a more localized treatment with less collateral damage.” ■

1. Ansari E, Gandhewar J. Long-term efficacy and visual acuity following transscleral diode laser photocoagulation in cases of refractory and non-refractory glaucoma. *Eye (Lond)*. 2007;21(7):936-940.
2. Gedde SJ, Schiffman JC, Feuer WJ, Herndon LW, Brandt JD, Budenz DL. Three-year follow-up of the Tube Versus Trabeculectomy Study. *Am J Ophthalmol*. 2009;148(5):670-684.
3. Gaasterland DE. Diode laser cyclophotocoagulation. Technique and results. *Glaucoma Today*. March 2009;7(2):35-38.
4. Tan AM, Chockalingam M, Aquino MC, et al. Micropulse transscleral diode laser cyclophotocoagulation in the treatment of refractory glaucoma. *Clin Experiment Ophthalmol*. 2010;38(3):266-272.

---

## Case Study

BY JEFFREY KAMMER, MD

---

### CASE PRESENTATION

A 65-year-old white woman presented with 20/100 visual acuity in her right eye (secondary to refractive amblyopia) and 20/20 in her left eye. When first examined, her left eye was found to have a pedunculated lesion at 8 o’clock in the peripheral iris, with some seed-

ing in the surrounding iris stroma. Her IOP measured 35 mm Hg OS despite topical therapy with dorzolamide hydrochloride-timolol maleate ophthalmic solution (Cosopt; Merck & Co., Inc.), brimonidine (Alphagan; Allergan, Inc.), and bimatoprost (Lumigan; Allergan, Inc.). Transillumination did not reveal ciliary body

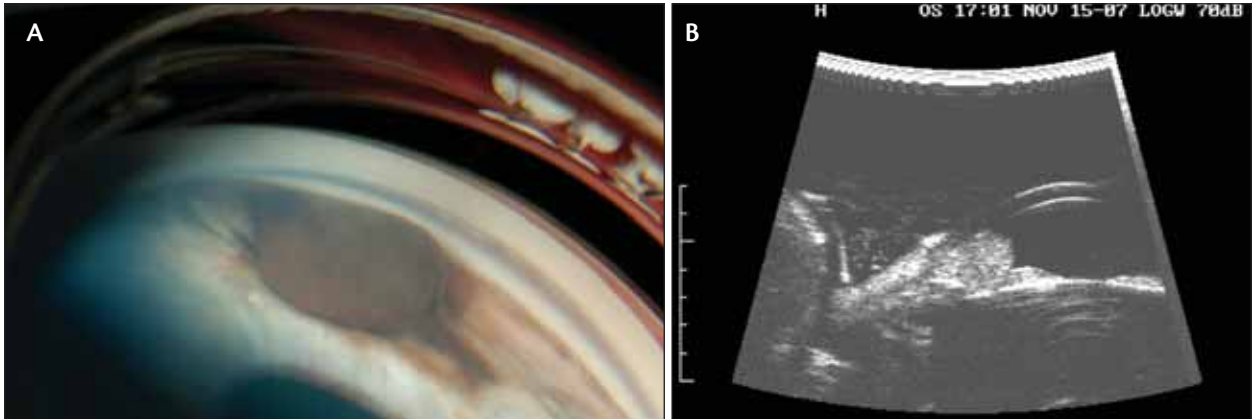


Figure. Presumed melanocytoma in a 65-year-old white woman viewed with a gonioscens (A) and ultrasound biomicroscopy (B).

involvement, and ultrasound biomicroscopy suggested that the mass was localized to the peripheral iris and anterior chamber, with no evidence of pars plana or pars plicata involvement. This lesion was presumptively diagnosed as an iris melanocytoma. An excisional biopsy was recommended to confirm the diagnosis, but the patient chose observation rather than risk complications in her seeing eye (Figure).

#### TREATMENT PROTOCOL

The malignant potential of an iris melanocytoma, while very low, made it difficult to suggest any filtering surgery in this patient. I ultimately recommended transscleral cyclophotocoagulation (TSCPC) in the patient's left eye, and she was amenable to this therapeutic modality. During the procedure, I slowly increased the power settings from 1,750 to 2,000 mW until I heard the audible "pop," at which point, I adjusted my final power setting to just below that level (1,900 mW). I performed 16 applications with a 2,000-millisecond duration, skipping the 3- and 9-o'clock limbal positions. This eye was heavily pigmented, so I opted to slightly under-treat (16 instead of 24 applications) to avoid releasing too much pigment, with the knowledge that I could easily augment her treatment at a later date.

#### RESULTS

The first day postoperatively, the patient had a visual acuity of 20/50, and her IOP was still elevated (35 mm Hg) on the same aggressive IOP-lowering regimen (dorzolamide-timolol, brimonidine, and bimatoprost). This persistently elevated IOP was likely due to the treatment-induced release of pigment and inflammation. One week postoperatively, her visual acuity improved to 20/25, and her IOP was 20 mm Hg on dorzolamide-timolol and bimatoprost. By 3 weeks after TSCPC, her Snellen visual acuity was back to 20/20, with an IOP of 14 mm Hg on bimatoprost dosed twice daily.

#### CONCLUSION

There is a lot of discussion these days about tailoring the surgical intervention to the patient, and this is an excellent example of putting this theory into practice. In this case, I chose the nonpenetrating diode laser TSCPC in lieu of other incisional modalities to minimize the risk of metastases in this otherwise healthy patient. This case illustrates that, when used appropriately, TSCPC can be a safe and effective treatment modality in patients with excellent baseline vision. ■

#### WATCH IT NOW ON EYETUBE.NET

Using your smartphone, photograph the QR code to watch the video on Eyetube.net. If you do not have a QR reader on your phone, you can download one at [getscanlife.com](http://getscanlife.com).

Direct link to video of Dr. Kammer's presentation: <http://eyetube.net/?v=sirip>



Direct link to video of Dr. Radcliffe's presentation: <http://eyetube.net/?v=dudag>



Direct link to video of Dr. Vold's presentation: <http://eyetube.net/?v=noomu>



